



Bone Preservation in Dehiscence-Type Defects Using Composite Biphasic Calcium Sulfate Plus Biphasic Hydroxyapatite/ β -Tricalcium Phosphate Graft: A Histomorphometric Case Series in Canine Mandible

Eli E. Machtei, DMD,* Doron Rozitsky, MSD, DMD,† Hadar Zigdon-Giladi, DMD, PhD,‡ and Liran Levin, DMD§

Dehiscence-type defects associated with extraction sockets present a functional and esthetic challenge to the dental team. This is an ever-growing concern in an era when implant-based reconstruction is often the treatment of choice.¹

After extraction, a mean of 3.87-mm loss in crestal bone width and 1.53-mm loss in crestal height were reported. This crestal bone loss varies by tooth type, position, and dimension of the socket.² Ridge preservation after extraction has been shown to be effective and predictable in reducing the postoperative buccolingual vertical bone loss by approximately 50%.³ Different barrier membranes and

Objectives: To examine bone formation in dehiscence defects using biphasic hydroxyapatite/ β -tricalcium phosphate plus biphasic calcium sulfate (BCP/BCS).

Material: After extractions, 24 mandibular buccal dehiscence defects (3×3 mm) were treated with BCP/BCS (E), membrane (MC), or control (NC). Histology and histomorphometric analysis were performed.

Results: After 6 weeks, bone formation was noticeable in most sites. In subsequent phases, the woven bone was gradually remodeled into lamellar bone and marrow. Vertical new bone height in the E and MC groups (1.06 and 0.85 mm.) was substantially greater than that in the NC group (-0.28 mm). For all

groups, there was an overall increase in the height of the newly formed bone through the observation. At week 12, the vertical bone height was 1.95, 2.07, and 0.29 mm, respectively. The mean new bone area in the E and MC groups was much greater than that in the NC group (2.85, 2.80, and -0.20 mm², respectively). Percent new bone in all 3 groups was similar (36.25%, 34.84%, and 28.34%, respectively).

Conclusions: This study demonstrates the efficacy of BCP/BCS graft for bone augmentation in dehiscence-type extraction socket defect. (Implant Dent 2013;22:590–595)

Key Words: ridge preservation, dehiscence, calcium phosphate, calcium sulfate, regeneration

*Professor and Chairman, Department of Periodontology, Rambam HCC School of Graduate Dentistry, and Faculty of Medicine, Technion (Israel Institute of Technology), Haifa, Israel; Visiting Associate Professor, Division of Periodontology, Department of Oral Medicine, Infection and Immunity, Harvard Faculty of Dental Medicine, Boston, MA.

†Resident, Department of Periodontology, Rambam HCC School of Graduate Dentistry, and Faculty of Medicine, Technion (Israel Institute of Technology), Haifa, Israel.

‡Head, Mineralized Tissue Laboratory, Department of Periodontology, Rambam HCC School of Graduate Dentistry, and Faculty of Medicine, Technion (Israel Institute of Technology), Haifa, Israel.

§Senior Lecturer, Department of Periodontology, Rambam HCC School of Graduate Dentistry, and Faculty of Medicine, Technion (Israel Institute of Technology), Haifa, Israel.

Reprint requests and correspondence to: Eli E. Machtei, DMD, School of Dental Medicine, Harvard Medical Center, 188 Longwood Avenue, Boston, MA 02115, Phone: 617-4321359, Fax: 617-4321897, E-mail: eli_machtei@hsdm.harvard.edu

ISSN 1056-6163/13/02206-590
Implant Dentistry
Volume 22 • Number 6
Copyright © 2013 by Lippincott Williams & Wilkins

DOI: 10.1097/ID.0b013e3182a62748

grafting materials have been shown to be effective for this purpose: Using xenogenic bone graft in humans, Barone et al⁴ were able to show less reduction in bone width (2.5 ± 1.2 vs 4.3 ± 0.8 mm) and height (0.7 ± 1.4 mm) versus controls (3.6 ± 1.5 mm). Using decalcified, freeze-dried bone allograft (DFDBA) in a putty carrier, Hoang and Mealey⁵ were able to report 1.5-mm loss in horizontal

dimension and 1-mm loss in vertical height in extraction sockets in humans. Alloplastic materials were also shown to be successful in such defects; these include bioactive glass,⁶ β -tricalcium phosphate (β -TCP),⁷ and calcium sulfate (CS).⁸ To the contrary, placement of autogenous bone particle in extraction sockets failed to prevent this resorption.⁹ Barrier membranes have also been shown to help in ridge preservation, both

as a stand-alone^{10,11} and in conjunction with various implantable materials.^{12,13}

Some of the grafting materials require extended period for complete resorption.¹⁴ This might be a virtue (especially for larger defects or when the site is not scheduled for implant placement) or a burden (if an implant is desired in the same site). To the contrary, some materials, such as CS, have demonstrated faster resorption patterns that might not allow for optimal replacement by native bone.¹⁵

Dehiscence-type defect associated with the extraction socket also presents a problem if an implant is desired in such site. The missing radicular bone in such defects hinders the use of particulated bone graft alone due to the lack of containment and thus space for the graft material.¹⁶

Biphasic calcium phosphate (BCP) is an intimate mixture of hydroxyapatite (HA) and β -TCP. β -TCP is almost completely resorbed in 6 to 24 months after implantation,¹⁷ whereas recent studies have demonstrated that HA may undergo some degree of chemical dissolution *in vivo*, and some cell-mediated remodeling of HA has also been reported.^{18,19}

However, CS is well tolerated when used to fill alveolar bone defects and undergoes rapid and complete resorption without eliciting a significant inflammatory response.^{20,21} Despite its virtues, CS has some shortcomings, especially rapid and complete resorption. Furthermore, it sometimes does not adhere well enough to the underlying bone, especially when osseous bleeding is encountered, which may cause separation and thus failure of the regenerative procedure.²² Biphasic calcium sulfate (BCS) is an innovative material that possesses the virtues of CS without most of its deficiencies. Once it encounters saline, the granulated powder forms a rigid structure, which is highly crystalline, despite the interfering environment (blood and saliva).

The aim of this study was to evaluate histologically and histomorphometrically the bone formation in mandibular dehiscence-type extraction socket defects using a composite bone graft of BCP plus BCS and compare it with membrane barrier and sham operation.

MATERIALS AND METHODS

The study was initially submitted and approved by the Animal Experimentation Committee of the Faculty of Medicine at the Technion, Israel Institute of Technology. Two healthy mongrel dogs were used in this study as per recent regulation of animals allocated to scientific research.

Clinical Procedures

The dogs were at first anesthetized using general anesthesia, which initially included premedication with 0.1 mg/kg of acepromizine + 4 mg/kg of Demerol intramuscularly; induction with 4 to 6 mg/kg of propofol intravenously; maintenance with 2% isoflurane delivered by intermittent positive pressure ventilation. In addition, infiltration with local anesthesia (2% lidocaine with epinephrine in the ratio of 1:100,000) was given to the surgical site. Full-thickness mucoperiosteal flaps were elevated and mandibular premolars (PM, 1–4) were hemisected and then carefully extracted. Next, standardized buccal dehiscence defects (height, 3 mm; width, 3 mm) were surgically created using a diamond bur with copious saline irrigation on the buccal aspect of all the mandibular premolars sockets sites (2 defects for PM₃ and PM₄). Thus, 24 defects were available. Each dehiscence defect was randomly assigned using a designated allocation chart to one of the following 3 groups (Fig. 1).

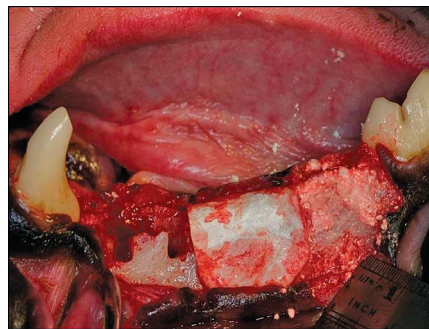


Fig. 1. Left side demonstrating the 3 treatment modalities: on the PM1 and PM2 are negative controls treated with coronally positioned flap only. PM3 was treated with membrane barrier. The membrane does not collapse into the space, as there are sufficient walls to support it. PM4 was treated with a composite graft. It fills the space and the dehiscence in the labial wall.

1. Experimental group (E): 12 defects were filled with BCP/BCS mixed in a 1:2 ratio (BCP: 100- to 1000- μ m particle size, 4BONE; Biomatlante, Vigneux de Bretagne, France and BCS: 10- to 1600- μ m particle size, BondBone; Augma Biomaterials, Caesarea, Israel).
2. Membrane control group (MC): 6 defects were covered with a resorbable porcine skin-sourced collagen membrane (4BONE RCM; Biomatlante). The size of the defect and the existing 4 walls prevented the collapse of the membrane and ensured preservation of the space beneath the membrane.
3. Negative control group (NC): 6 sham operation defects (blood clot only).

Flaps were coronally positioned to achieve primary closure and sutured using 4-0 monofilament sutures (Biosyn; Covidien, Dublin, Ireland).

Postoperatively, the dogs received antibiotics (3 mL/d of cefalexin subcutaneously) for 1 week and analgesics (intramuscularly 4 mg/kg of Tramadol; Grünenthal GmbH, Aachen, Germany) for 3 days. Mouthwash chlorhexidine gluconate 0.2% (Tarodent; Taro Pharmaceutical, Haifa, Israel) was prescribed twice daily for 10 days.

These surgeries were staggered within the dogs, thus creating observation periods of 6 and 10 weeks for dog 1 and 8 and 12 weeks for dog 2. At week 12, the dogs were euthanized by induction of deep anesthesia followed by an overdose of pentobarbital sodium. The mandibles were removed and scanned using computed tomography (Brilliance CT 64-channel scanner; Philips Electronics, Amsterdam, the Netherlands) to demonstrate radiographically hard tissue formation in the defect sites.

Histological Processing and Analysis

Soft tissue was separated, and the mandibles were fixed using 10% neutral buffered formalin and decalcified through hydrochloric acid. The specimens were cut into blocks (buccolingual) of approximately 500 μ m in width. The samples were transferred through baths of progressively more concentrated ethanol to remove the

Table 1. Histomorphometric Measurement of the Dehiscence Sites After Treatment

Variable	Mean			6 wk			8 wk			10 wk			12 wk		
	Exp	MC	NC	Exp	MC	NC	Exp	MC	NC	Exp	MC	NC	Exp	MC	NC
	Percent new bone	36.25	34.84	28.36	36.63	37.82	29.52	35.18	30.95	24.45	39.19	38.87	33.97	36.98	31.73
New bone height (mm)	1.06	0.85	-0.28	0.33	0.29	-0.21	1.25	0.62	-0.72	0.71	0.43	-0.48	1.95	2.07	0.29
New bone area (mm ²)	2.85	7.12	0.76	1.59	0.70	-0.10	2.86	2.06	-1.63	2.23	1.33	0.15	4.73	7.12	0.76

Mean values are given for each of the treatment modalities (Exp, MC, NC) at the different time points. Exp, BCS/BCP; MC, membrane only; NC, primary closure only.

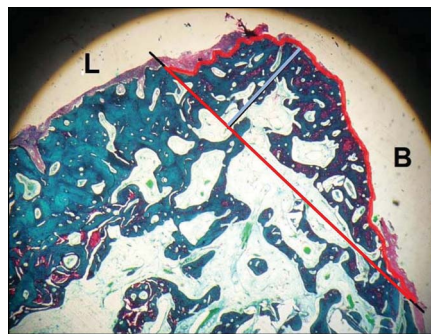


Fig. 2. To perform the histomorphometric measurements, a line was drawn from the lingual crest to the apical border of the dehiscence on the labial wall (red). The height of the newly formed bone was measured vertically from there (blue bar). The area of newly formed bone is bordered by the red lines.

water. This was followed by a hydrophobic clearing agent, xylol, to remove alcohol. Next, molten paraffin wax, the infiltration agent, replaced the xylol. Finally, samples were placed into molds along with liquid paraffin wax, which was then hardened by cooling and sectioned (8 μ m) using a steel knife mounted in a microtome (RM 2135; Leica Microsystems, Wetzlar, Germany).

Sections were mounted on a glass microscope slides using paraffin section mounting bath (Electron Microscopy Sciences, Hatfield, England), which allowed easy manipulation of the sections, avoiding problems with wrinkles, folds, and distortion. The glass slides were then placed in a warm oven for approximately 15 minutes to help the section adhere to the slide. The mounted sections were treated with the 2 types of stains: hematoxylin and eosin and picrosirius red. The latter is especially good to stain collagen and allows us to differentiate between differing forms of collagen fibers, enabling to quantify the amount of collagen in a given area and assess bone quality (lamellar or woven bone).

Histomorphometric Analysis

Histomorphometric evaluation of the samples was performed at $\times 2$ objective; 3 slides per sample were taken from the center (mesiodistal) of the defects. The system consists of Brightfield microscope (Olympus CH40, Tokyo, Japan) fitted with a color video CCD camera WAT 202D (Watec Digital, Middletown, NY). After

digitization of the picture, the histomorphometric data were acquired using a picture analysis program (AnalySiS 3.0; Soft-Imaging Software, Münster, Germany).

For each defect, measurements were taken on all the 3 slides (center cuts 8 μ m apart), and an arithmetic average was calculated per site and then for all time points of each treatment modality (Table 1).

The following parameters were recorded (Fig. 2):

1. Bone density: Percent of the newly formed bone at the coronal aspect of the defect was calculated from the total volume.
2. New bone height: The height (in micrometers) of the newly formed bone above and beneath (negative values) the line connecting the buccal and lingual bone crests at the middle of the defect.
3. New bone area (in square micrometers): Percent of the newly formed bone above and beneath (negative values) the line connecting the buccal and lingual bone crests at the middle of the defect.

RESULTS

Histological Results

Healing was uneventful in all groups, and all membranes remained submerged. After 6 weeks of healing, bone formation was evident in most sites, and trabeculae of newly formed bone could be seen in the previously dehiscence sites. In subsequent phases, the woven bone (primary or immature) was gradually remodeled into lamellar bone (secondary or mature) and marrow. Therefore, the trabeculae had a core of woven bone, which was surrounded by lamellar bone (Fig. 3, A). The trabeculae became thicker through the deposition of additional woven bone. The woven bone was reinforced by the deposition of so-called lamellar bone that had its collagen fibers organized not in a woven but in a lamellar concentric pattern. Areas of bone matrix containing collagen fibers projecting in several directions were observed. Such areas were interpreted

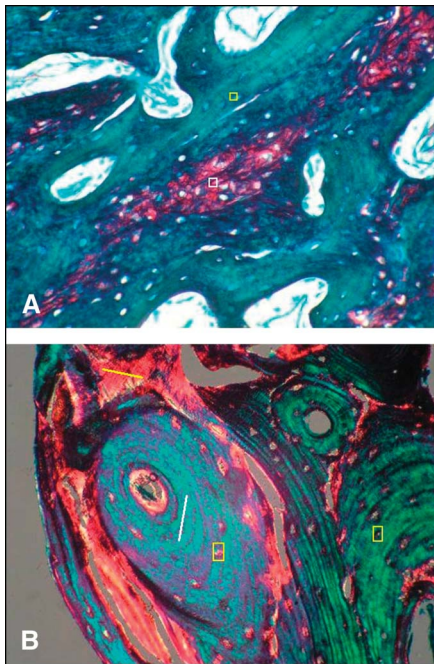


Fig. 3. **A**, Picrosirius red stain at $\times 20$ magnification showing an area of woven bone (white box) surrounded by lamellar bone (yellow box). **B**, Polarized picrosirius red stain at $\times 20$ magnification showing osteocytes within lacunae of bone (yellow box), residual woven bone (yellow line), and lamellar bone (white lines).

as residual woven bone (Fig. 3, B, MC group).

In all groups, concentric lamellar structures and haversian canals were observed, suggesting the presence of lamellar bone. The collagen fibers in each lamella were regularly arranged and displayed anisotropy (birefringence) when examined by polarizing microscopy. Depending on the state of development of the bone, it was occasionally possible to find bone trabeculae, which were lined by a layer of osteoblasts. As the osteoblasts continued to lay down osteoid and deposited the first lamellae occasionally, such cells were trapped in the matrix and became osteocytes within the lacunae of the bone. Primitive blood vessels were seen in the connective tissue located between the trabeculae. Interrupted/partially resorbed lamellae and incremental lines were also frequently observed in the newly formed bone, indicating regions of new bone formation.

Histomorphometric Results

Mean vertical height of the newly formed bone in the E and MC groups

(1.06 and 0.85 mm, respectively) was substantially greater at 6 weeks than that in the NC group (-0.28 mm). In fact, in most of the time points, the NC group had a net loss of vertical bone height. For all groups, there was an overall increase in the height (ie, vertical growth) of the newly formed bone through the observation period (6–12 weeks). At week 12, the vertical bone height was 1.95, 2.07, and 0.29 mm, respectively (Table 1).

The mean area of the newly formed bone in the E and MC groups was greater than that in the NC group (2.85, 2.80, and -0.20 mm² for these 3 groups, respectively). Again, in many of the specimens, the NC had a net loss of bony mass post-operatively. In general, there was an overall increase in the area of the newly formed bone through the weeks. Finally, at week 12, new bone area was 4.73 in the E group, 7.12 in the MC group, and 0.76 mm² in the NC group.

Percentage of new bone in the E and MC groups was, in general, only slightly higher than that in the NC group (36.25%, 34.84%, and 28.34%, respectively). This bone density seemed quite stable through the observation period (ranging between 25% and 40% in the various groups and time points), thus suggesting that most of the new bone formation takes place early in the healing process. At week 12, the corresponding percentile new bone was 36.98% in the E group, 31.73% in the MC group, and 25.40% in the NC group.

The macroscopic observation at week 12 further supported the histological finding (Fig. 4). In the NC sites

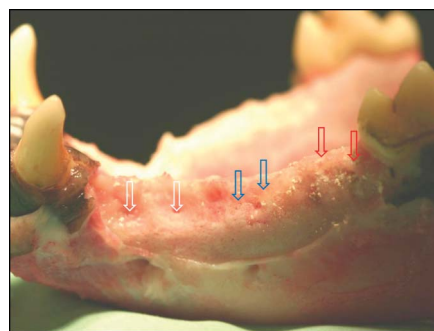


Fig. 4. Macroscopic view of a mandibular left side at week 12. In the area corresponding to the NC site, a noticeable depression is evident, whereas in the E site, the ridge seems to have filled completely.

(white arrows), a buccal depression could easily be seen in all time points, whereas in the E group (red arrows) and, to a lesser extent, in the MC group (blue arrows), the buccal wall was relatively intact. These differences were noticeable especially after 10 and 12 weeks of healing periods.

DISCUSSION

In the present study, bone density and new bone formation were greater in the E group compared with the NC group and in most slides even greater than the MC group. At week 12, 1.5 to 2 mm of linear bone growth and 4 to 5 mm² bone area, of which 35% to 40% is new bone fill, were observed. The present model of dehiscence-type defect associates with extraction site, whereas a common clinical feature has seldom been studied before. Using a similar model in a 6-month canine study, von Arx et al²³ have reported less favorable results for DFDBA and β -TCP compared to autogenous bone blocks when covered with an expanded polytetrafluoroethylene membrane barrier (percent hard tissue fill of $74.3 \pm 15.8\%$, $76.6 \pm 14.4\%$, and $91.1 \pm 7.9\%$, respectively). However, differences in the observation period, defects size, and outcome measurements do not allow for the comparison of the results. In a similar canine study, Kim et al¹⁶ have shown greater radiographic bone density in defects treated with combination of xenogenic bone mineral (BM) graft plus membrane compared to BM alone or sham operation after 8 to 16 weeks; however, histological data were not available.

The regenerative effect of β -TCP plus CS has not been studied before for alveolar ridge augmentation; however, Sukumar et al²⁴ have recently used similar composite graft for the treatment of human intrabony periodontal defects adjacent to teeth. They reported an overall pocket depth reduction and clinical attachment level gain of approximately 2 mm. Using a composite CS plus particulate HA graft in an orthopedic bone defects, Parsons et al²⁵ were able to show good regenerative response. They have suggested that early resorption of the CS leave

porosity that would enhance the ingrowth of bone. In addition, they found that the CS acted as a binder and improved the handling characteristics of HA. Urban et al²⁶ implanted a composite CS and calcium phosphate (CP) graft into a critical-sized defect in canines. The composite material gave greater bone fill than did the unembellished CS. The physical properties of the bone regenerated with the CS/CP composite were similar to native bone.

Schwarz et al²⁷ compared β -TCP/HA (Bone ceramic, Straumann AG, Basel, Switzerland) to collagen/BM grafts (BioOss collagen Geistlich Pharma AG, Wolhusen, Switzerland) in dehiscence-type defects adjacent to dental implants in canines. At week 9, both materials resulted in new bone formation; however, for both groups, residues of the materials were evident with no osteoclastic activity on its surface. More recently, Mardas et al²⁸ examined β -TCP/HA or BM both in conjunction with collagen membrane for ridge preservation of extraction sockets with no apparent difference between the groups.

Several limitations of the present study should be recognized: primarily, the limited number of dogs. Thus, further control groups (membrane and bone graft or bone graft only) were not possible because it would have further decreased the number of sites in each treatment arm. These limited observations have not permitted us to compare the groups statistically in the different time points and treatment arm.

Residual graft materials were not identified in the specimens and any remaining voids thus suggesting complete resorption. The absence of particle voids even at week 6 suggests that the scaffold properties of the experimented material beneficially influence graft resorption and bone regeneration rate at least in the canine model. In human, Sbordone et al²⁹ have shown complete resorption of CS grafts 5 months postoperatively. Although complete resorption is expected for the BCS and β -TCP component of the composite graft, the absence of HA particles is somewhat more surprising. HA is generally considered to be a very slow-resorbing material. In humans, Piattelli et al³⁰ have shown that HA particles that were

implanted in intrabony periodontal defect have shown no signs of resorption 1 year postoperatively. To the contrary, Iafisco et al³¹ in a comparative study of HA particles have shown that smaller diameter, needle-shaped particles (3 μ m) underwent complete macroscopic resorption at week 4 compared to larger diameter, plate-shaped particles (30 μ m) that were still present at week 8. Likewise, Checchi et al,³² using nanocrystalline and biomimetic HA particles in extraction sockets showed that at 6 months of reentry, the residual HA particles were only 8% to 14% of the total core biopsy content. Thus, the small HA particle size, its relatively small proportion of the total graft material (<20%), and the rapid turnover in these sites might account for this phenomenon.

In the present study, membrane barrier was not used in conjunction with the bone graft. Recently, in a human study of β -TCP/collagen cones implanted in extraction sockets, with or without membrane barrier, Brkovic et al³³ reported greater horizontal and vertical bone loss when membrane was not used. Although membrane barriers were not assessed in this study, they might prove less critical than with other graft materials when it comes to the space-maintaining properties of such barriers. The mechanical properties of the composite graft material are more than sufficient to fill and maintain the space even in the absence of the labial wall. This is mainly attributed to the BCS with its fast-setting and stable structure, which enables it to preserve the desired 3-dimensional space. Also, the porosity of BCP enables blood vessels growing into the graft. In addition, it increases the overall surface area of the graft, which might enable bone morphogenic proteins to adsorb, thus reaching greater local concentration. To the contrary, a barrier may be beneficial via its exclusion properties, especially when dealing with larger defect that requires extended healing time.

CONCLUSIONS

The present case series suggests that BCP plus BCS may have the potential for bone regeneration in

dehiscence-type defects associated with extraction sockets. Larger preclinical and human studies are necessary to validate these results.

DISCLOSURE

This study was partially supported by an educational grant by the MIS implant company. The authors claim to have no financial interest, either directly or indirectly, in the products or information listed in the article.

REFERENCES

1. Youngson C. Summary of: The influence of specialty training, experience, discussion and reflection on decision making in modern restorative treatment planning. *Br Dent J*. 2011;210:164–165.
2. Van der Weijden F, Dell'Acqua F, Slot DE. Alveolar bone dimensional changes of post-extraction sockets in humans: A systematic review. *J Clin Periodontol*. 2009;36:1048–1058.
3. Weng D, Stock V, Schliephake H. Are socket and ridge preservation techniques at the day of tooth extraction efficient in maintaining the tissues of the alveolar ridge? *Eur J Oral Implantol*. 2011;4:59–66.
4. Barone A, Aldini NN, Fini M, et al. Xenograft versus extraction alone for ridge preservation after tooth removal: A clinical and histomorphometric study. *J Periodontol*. 2008;79:1370–1377.
5. Hoang TN, Mealey BL. Histological comparison of healing after ridge preservation using human demineralized bone matrix putty with one versus two different-sized bone particles. *J Periodontol*. 2012;83:174–181.
6. Froum S, Cho SC, Rosenberg E, et al. Histological comparison of healing extraction sockets implanted with bioactive glass or demineralized freeze-dried bone allograft: A pilot study. *J Periodontol*. 2002;73:94–102.
7. Horowitz RA, Mazor Z, Miller RJ, et al. Clinical evaluation alveolar ridge preservation with a beta-tricalcium phosphate socket graft. *Compend Contin Educ Dent*. 2009;30:588–590, 592, 594 passim; quiz 604, 606.
8. Guamieri R, Pecora G, Fini M, et al. Medical grade calcium sulfate hemihydrate in healing of human extraction sockets: Clinical and histological observations at 3 months. *J Periodontol*. 2004;75:902–908.
9. Araújo MG, Lindhe J. Socket grafting with the use of autologous bone: An experimental study in the dog. *Clin Oral Implants Res*. 2011;22:9–13.

10. Lekovic V, Camargo PM, Klokkevold PR, et al. Preservation of alveolar bone in extraction sockets using bioabsorbable membranes. *J Periodontol*. 1998;69:1044–1049.
11. Barboza EP, Stutz B, Ferreira VF, et al. Guided bone regeneration using non-expanded polytetrafluoroethylene membranes in preparation for dental implant placements—A report of 420 cases. *Implant Dent*. 2010;19:2–7.
12. Mardas N, Chadha V, Donos N. Alveolar ridge preservation with guided bone regeneration and a synthetic bone substitute or a bovine-derived xenograft: A randomized, controlled clinical trial. *Clin Oral Implants Res*. 2010;21:688–698.
13. Iasella JM, Greenwell H, Miller RL, et al. Ridge preservation with freeze-dried bone allograft and a collagen membrane compared to extraction alone for implant site development: A clinical and histologic study in humans. *J Periodontol*. 2003;74:990–999.
14. Mordenfeld A, Hallman M, Johansson CB, et al. Histological and histomorphometrical analyses of biopsies harvested 11 years after maxillary sinus floor augmentation with deproteinized bovine and autogenous bone. *Clin Oral Implants Res*. 2010;21:961–970.
15. Jardelino C, Takamori ER, Hermida LF, et al. Porcine peritoneum as source of biocompatible collagen in mice. *Acta Cir Bras*. 2010;25:332–336.
16. Kim M, Kim JH, Lee JY, et al. Effect of bone mineral with or without collagen membrane in ridge dehiscence defects following premolar extraction. *In Vivo*. 2008;22:231–236.
17. Artzi Z, Weinreb M, Givol N, et al. Biomaterial resorption rate and healing site morphology of inorganic bovine bone and beta-tricalcium phosphate in the canine: A 24-month longitudinal histologic study and morphometric analysis. *Int J Oral Maxillofac Implants*. 2004;19:357–368.
18. Hing KA, Best SM, Tanner KE, et al. Mediation of bone ingrowth in porous hydroxyapatite bone graft substitutes. *J Biomed Mater Res A*. 2004;68:187–200.
19. Porter AE, Patel N, Skepper JN, et al. Comparison of in vivo dissolution processes in hydroxyapatite and silicon-substituted hydroxyapatite bioceramics. *Biomaterials*. 2003;24:4609–4620.
20. Bell WH. Resorption characteristics of bone and bone substitutes. *Oral Surg Oral Med Oral Pathol*. 1964;17:650–657.
21. Thomas MV, Puleo DA. Calcium sulfate: Properties and clinical applications. *J Biomed Mater Res B Appl Biomater*. 2009;88:597–610.
22. Robinson D, Alk D, Sandbank J, et al. Inflammatory reactions associated with a calcium sulfate bone substitute. *Ann Transplant*. 1999;4:91–97.
23. von Arx T, Cochran DL, Hermann JS, et al. Lateral ridge augmentation using different bone fillers and barrier membrane application. A histologic and histomorphometric pilot study in the canine mandible. *Clin Oral Implants Res*. 2001;12:260–269.
24. Sukumar S, Drizhal I, Paulusová V, et al. Surgical treatment of periodontal intrabony defects with calcium sulphate in combination with beta-tricalcium phosphate: Clinical observations two years post-surgery. *Acta Medica (Hradec Králove)*. 2011;54:13–20.
25. Parsons JR, Ricci JL, Alexander H, et al. Osteoconductive composite grouts for orthopedic use. *Ann N Y Acad Sci*. 1988;523:190–207.
26. Urban RM, Turner TM, Hall DJ, et al. Increased bone formation using calcium sulfate-calcium phosphate composite graft. *Clin Orthop Relat Res*. 2007;459:110–117.
27. Schwarz F, Herten M, Ferrari D, et al. Guided bone regeneration at dehiscence-type defects using biphasic hydroxyapatite + beta tricalcium phosphate (Bone Ceramic) or a collagen-coated natural bone mineral (BioOss Collagen): An immunohistochemical study in dogs. *Int J Oral Maxillofac Surg*. 2007;36:1198–1206.
28. Mardas N, D'Aiuto F, Mezzomo L, et al. Radiographic alveolar bone changes following ridge preservation with two different biomaterials. *Clin Oral Implants Res*. 2011;22:416–423.
29. Sbordone L, Bortolaia C, Perrotti V, et al. Clinical and histologic analysis of calcium sulfate in treatment of a post-extraction defect: A case report. *Implant Dent*. 2005;14:82–87.
30. Piattelli A, Mangano C, Donzelli R, et al. Light and laser scanning microscopy analysis of hydroxyapatite used in periodontal osseous defects in man: Evidence of a different resorption pattern in bone and soft tissues. *Bull Group Int Rech Sci Stomatol Odontol*. 1993;36:115–120.
31. Iafisco M, Varoni E, Battistella E, et al. The cooperative effect of size and crystallinity degree on the resorption of biomimetic hydroxyapatite for soft tissue augmentation. *Int J Artif Organs*. 2010;33:765–774.
32. Checchi V, Savarino L, Montevecchi M, et al. Clinical-radiographic and histological evaluation of two hydroxyapatites in human extraction sockets: A pilot study. *Int J Oral Maxillofac Surg*. 2011;40:526–532.
33. Brkovic BM, Prasad HS, Rohrer MD, et al. Beta-tricalcium phosphate/type I collagen cones with or without a barrier membrane in human extraction socket healing: clinical, histologic, histomorphometric and immunohistochemical evaluation. *Clin Oral Invest*. 2012;16:581–590.